

## CLINICAL REPORT

### Complete denture as a myofunctional therapeutic appliance to guide the patient into centric relation –A clinical report

Gayathrie B\*, Suganya S\*\*, Murugesan K\*\*\*

#### ABSTRACT

One of the most difficult tasks to accomplish in complete denture treatment is retruding the mandible to obtain the centric relation (CR) record 1-8. This can occur due to the absence of synchronization in groups of opposing muscles when the patients are asked to close in the retruded position. Several methods have been designated for helping the edentulous patient to retrude their mandibles into CR 2-9. The tongue can be utilized to help the edentulous patients to record CR 2,4,9-14. When the tip of the tongue is turned back toward the soft palate, it exerts a muscular pull on the mandible in a backward direction to the desired position. Many appliances that guide the mandible to the centric relation position have been utilized in the past. However, most of these appliances can compromise speech and oral hygiene. This article describes a simple procedure that enables the edentulous patient to retrude the mandible to its CR position and to reduce the hazards of protruding the mandible from its retruded position during closing the mouth to CR.

**Keywords:** Centric relation, myofunctional therapy

#### INTRODUCTION

The basis of recording centric records is to institute strategies as a starting point to improve occlusion with artificial teeth consistent with the numerous structures of masticatory apparatus including TMJ. It helps to sustain the physiologic and anatomic health of tissues. When maximum intercuspation is consistent with centric position, it brings stability to the prosthesis thus preserving the health of residual tissues 15.

#### CASE REPORT

A 72year old male reported to the department with complete edentulism. The patient was edentulous for seven years. His medical history revealed that he had hypertension and diabetes mellitus both of which were under medical control. During his visit, the patient complained of difficulty in mastication and deglutition. An extra-oral examination revealed competent lips with normal mouth opening, a concave facial profile, and prominent mentalis muscle. Intraorally, mandible deviation toward the right side and protrusion were observed, as well as limited movement of the tongue.

The patient was asked to place the tongue in different parts of the mouth to determine the extent of mandibular deviation. The patient could touch the anterior and median part of the hard palate with a slight deviation of the mandible. After maneuvering the tongue to the posterior part of the palate, he exhibited improved facial features and no right joint clicks; however, after a few minutes, he returned to his habitual position.

The treatment plan was to fabricate complete dentures at centric relation that the patient gave by placing his tongue to the posterior-most position. Maximum intercuspation was set at this position and the denture was processed with orthodontic brackets attached on buccal flanges on either side of both dentures. These brackets served as attachments to which elastics were attached and dentures were inserted intraorally as a single unit. This guided the mandible into the CR position and the dentures were used as a training appliance.

\*\*\* Professor, Department of Prosthodontics, SRM dental college, Ramapuram, Chennai-600089.  
\*\* Reader, Department of Prosthodontics, SRM dental college, Ramapuram, Chennai-600089.  
\* Post graduate, Department of Prosthodontics, SRM dental college, Ramapuram, Chennai-600089.

Preliminary impressions were made by using stock trays and irreversible hydrocolloid (DPI Algitek®). Definitive impressions were made by using custom trays made from auto-polymerizing acrylic resin

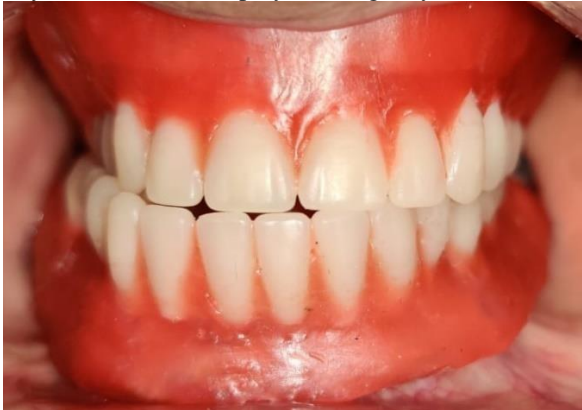

Figure 1: Habitual mandibular position

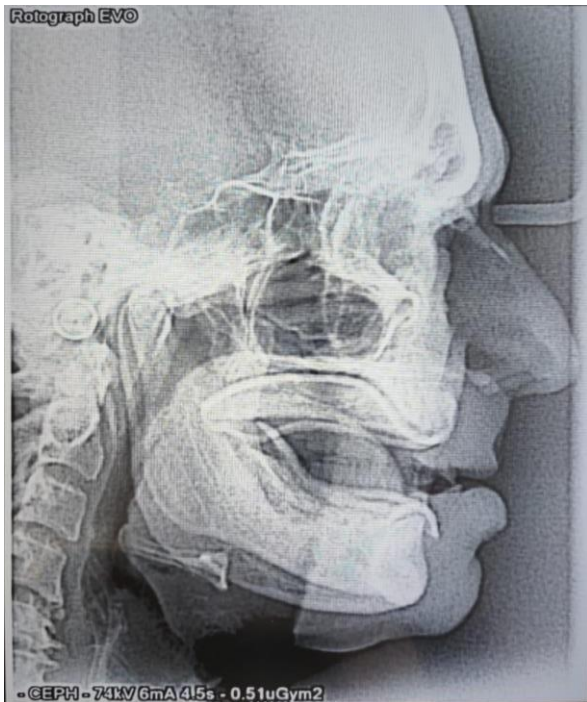

Figure 2: Lateral cephalogram

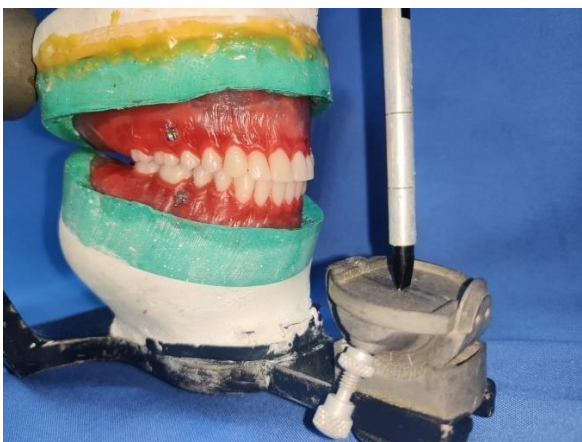


Figure 3: Incorporation of orthodontic brackets

(@DPI-RR cold cure-acrylic repair material) and zinc oxide eugenol impression material (@DPI Impression paste) after border molding with impression compound modelling plastic (@DPI PINNACLE; Tracing sticks).

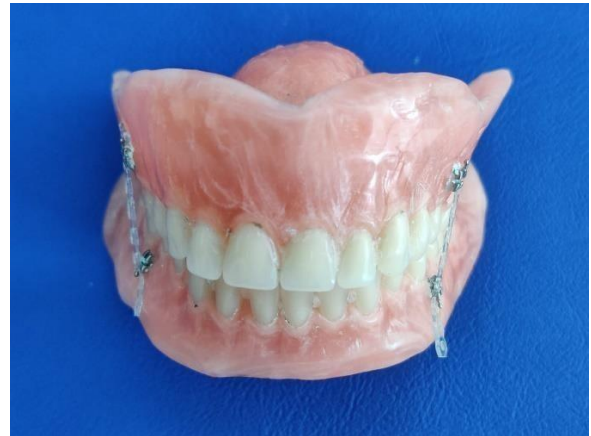

Figure 4: Upper and lower denture kept in maximum intercuspation using elastics

The mandibular relationship was recorded by asking the patient to elevate the tongue to the most posterior part of the palate that he was able to reach and close in the retruded position. The teeth arrangement was based on balanced occlusion. Trial dentures were evaluated. Still, the patient exhibited mandibular deviation and protrusion in his habitual mandibular position (figure 1) This position was confirmed by making a lateral cephalogram (figure 2). After the trial, orthodontic brackets were incorporated on the buccal flanges of both upper and lower dentures extra-orally (figure 3). Trial dentures were completely waxed up and then processed by using the conventional wax elimination technique. After finishing and polishing, the definitive dentures were evaluated intraorally. Both the dentures were removed and they were kept in the maximum intercuspation position.

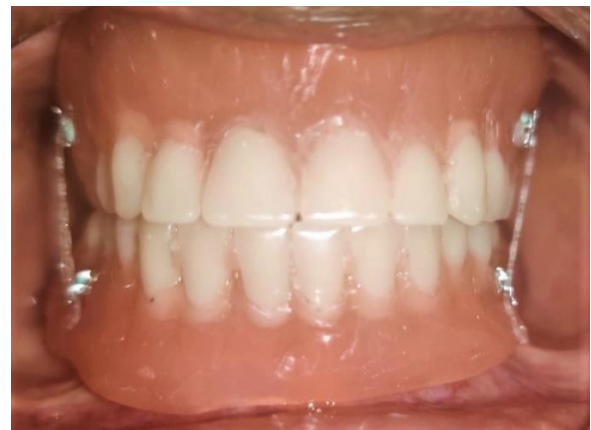

Figure 5 a: Intro-oral view of final denture

This position was locked using elastics which were attached to the orthodontic brackets (figure 4). Now both the dentures were inserted into the patient's mouth as a single unit (figure 5). At first, the maxillary denture

was positioned on the edentulous ridge following which the patient was asked to gently close his mouth. Since the dentures were already locked in maximum intercuspal position (centric relation), they served as a guide to help the patient close in centric relation position. After insertion, the patient was asked to remove the elastics. The patient was instructed to insert both the dentures as a single unit by following the same protocol for a minimum of three months. The patient was recalled after three months and denture evaluation was done. At this point, the patient was able to close in centric relation when the dentures were inserted separately without the use of elastics. He demonstrated the absence of mandibular deviation and protrusion with increased mastication and deglutition activity. Also, the patient subjectively indicated satisfaction with the treatment. At the end of the recall visit, orthodontic brackets were removed.

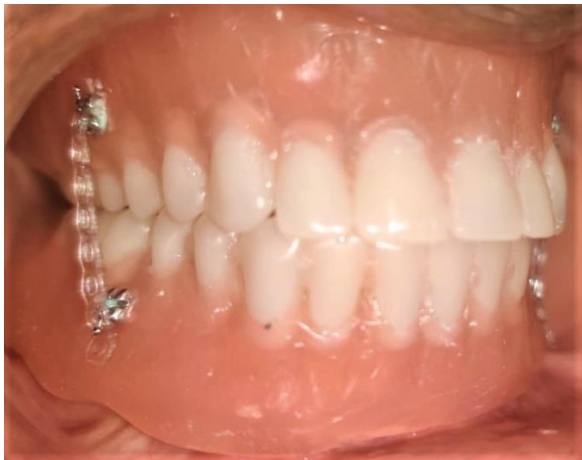

Figure 5 b: Intro-oral view of final denture

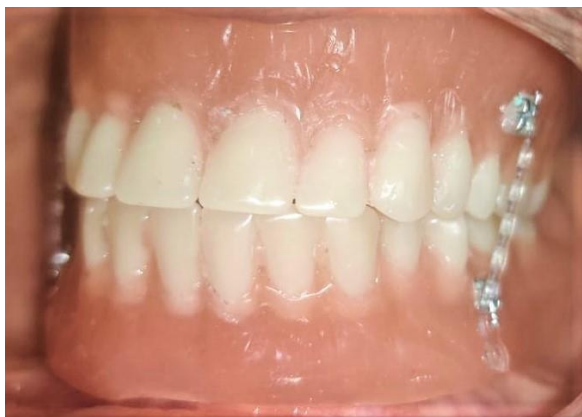

Figure 5 c: Intro-oral view of final denture

## DISCUSSION

To retrude the mandible into CR, patients are usually asked to elevate the tongue to the most posterior position of the palate and close in the retruded position or to close while swallowing 16-19. Therefore, the most posterior placement of a tongue guide in the palatal part of the maxillary denture can be beneficial. However, these appliances can cause deterioration in oral hygiene; consequently, the patient should be advised to

clean the appliance after every meal. It can also hinder tongue movement causing difficulty in speech and mastication. The appliance used in this study has brackets attached to the buccal flanges of the denture. Thus, food accumulation is minimal and the tongue movement is not affected. Balanced occlusion locked the mandible in one position, preventing tipping of the mandibular denture. Compared with monoplane occlusion, stable contact of the opposing teeth in CR was achieved, and sufficient masticatory efficiency was maintained. The success of therapy was defined by clinical evaluation of the patient's ability to masticate and swallow as well as maintain the mandible in CR for longer periods. Besides the improvements in swallowing, deglutition, and mastication, the advantage of this method includes regaining CR, correction of mandibular deviation and protrusion, improvement of facial features, strengthening of tongue muscles, low cost, ease of incorporation into the prosthesis and its easy removal. This report is based on the treatment of a single patient and does not include any standardized group measurements. Within these constraints, the results suggest that the method can benefit edentulous patients. Future studies are required to verify the effect of orofacial myofunctional therapy, as improvements are reported to remain for more than 1 year after treatment 20. Further enhancements to the maxillary denture may be made if required (more denture stimulators, applying orofacial regulation therapy).

## CONCLUSION

A straightforward method of orofacial myofunctional exercise using a modified complete maxillary and mandibular denture, was described. This procedure, useful in edentulous patients, led to the restoration and maintenance of centric relation.

## CONFLICT OF INTEREST

There is no conflict of interest

## REFERENCES

1. Rahn AO, Heartwell CM. Textbook of complete dentures. 5th ed. Philadelphia: Lea and Febiger; 1993. p. 275-304.
2. Hickey JC, Zarb GA, Bolender CL. Boucher's prosthodontic treatment for edentulous patients. 9th ed. St Louis: CV Mosby; 1985. p. 277-91.
3. Academy of Prosthodontics. Principles, concepts and practices in prosthodontics—1994. J Prosthet Dent 1995;73:73-94.
4. Myers ML. Centric relation records. Historical review. J Prosthet Dent 1982;47:141-5.
5. Yurkstas AA, Kapur KK. Factors influencing centric relation records in edentulous mouth. J Prosthet Dent 1964;14:1054-65.
6. Kapur KK, Yurkstas AA. An evaluation of centric relation records obtained by various techniques. J Prosthet Dent 1957;7:770-86.
7. Winkler S. Essentials of complete denture prosthodontics. 1st ed. Philadelphia: WB Saunders; 1979. p. 236-81.

8. Levin B, Sanders JL. Results of a survey of complete denture procedures taught in American and Canadian dental schools: an update. *J Prosthet Dent* 1985;54:302-6.
9. Fenn HRB, Liddelow KP, Grimson AP. *Clinical dental prosthetics*. 2nd ed. London: Staples Printers Limited; 1961. p. 172-222.
10. Boyanov B. Determining vertical dimension of occlusion and centric relation. *J Prosthet Dent* 1970;24:18-24.
11. Mack A. *Full dentures*. London: John Wright and Sons Limited; 1971. p.54-76.
12. Neil DJ, Nairn RI. *Complete denture prosthetics*. 2nd ed. London: John Wright and Sons Limited; 1975. p. 79-81.
13. Jacob RF. The traditional therapeutic paradigm: Complete denture therapy. *J Prosthet Dent* 1998;79:6-13.
14. Weinberg LA. The role of muscle deconditioning for occlusal corrective procedures. *J Prosthet Dent* 1991;66:250-5.
15. Bansal S, Palaskar J. Critical evaluation of various methods of recording centric jaw relation. *Journal of Indian Prosthodontic Society*. 2008 Dec 1;8(4).
16. Zarb GA, Hobkirk JA, Eckert SE, Jacob RF, Fenton AH, Finer Y, et al. *Prosthodontic treatment for edentulous patients. Complete dentures and implant-supported prostheses*. 13th ed. St. Louis: Elsevier Mosby; 2013. p. 180-200.
17. Myers ML. Centric relation records. Historical review. *J Prosthet Dent* 1982;47:141-5.
18. Yurkstas AA, Kapur KK. Factors influencing centric relation records in edentulous mouth. *J Prosthet Dent* 1964;14:1054-65.
19. Kapur KK, Yurkstas AA. An evaluation of centric relation records obtained by various techniques. *J Prosthet Dent* 1957;7:770-86.
20. Hägg MK, Tibbling LI. Effects on facial dysfunction and swallowing capacity of intraoral stimulation early and late after stroke. *Neuro Rehabil* 2015;36: 101-6.



**Corresponding author:**

Dr. S. Suganya,  
Reader, Department of Prosthodontics,  
SRM Dental College, Ramapuram, Chennai-600089.  
Phone: 9842831534  
e-mail : sssgn.84@gmail.com

*Copyright by the Editorial Board of the Journal of Clinical Prosthodontics and Implantology*