

## CASE REPORT

### Magnetic Sectional Denture for Microstomia Patient with Oral Submucous Fibrosis: A Case Report.

Amrutha S Sankaran<sup>a</sup>, Arun M<sup>b</sup>, Anjana Kurien<sup>c</sup>, Sheela K<sup>d</sup>

#### ABSTRACT

This article presents a case report of a patient with oral sub mucous fibrosis and subsequent microstomia , that resulted in restricted mouth opening. A magnetic sectional denture was planned for the maxillary arch to overcome the problem and a conventional denture was planned for the mandibular arch. Primary impressions were made, followed by sectional maxillary special trays for border molding. The record bases for the maxillary arch was fabricated in heat cure by incorporating magnets of 3mm diameter on the anterior alveolar ridge and middle part of mid palatal raphe region, and 5 mm magnet towards the posterior most part of mid palatal raphe region. The jaw relation was carried out, followed by teeth setting and wax try in. Finally the maxillary denture was processed in two sections and denture insertion was done. Satisfactory retention was achieved and phonetics was restored.

**Keywords:** Microstomia, Oral submucous fibrosis, Sectional impression, Sectional trays, Sectional denture.

**How to cite this article:** Amrutha S Sankaran, Arun M, Anjana Kurien, Sheela K. Magnetic Sectional Denture for Microstomia Patient with Oral Submucous Fibrosis: A Case Report. *J Clin Prosth Impl* 2023;5(2):51-55. <https://doi.org/10.55995/j-cpi.2023011>.

#### INTRODUCTION

A congenital or acquired decrease in the size of the oral aperture that is severe enough to affect quality of life, nutrition, and appearance is referred to as microstomia. Freeman-Sheldon, Treacher Collins, and Pierre Robin syndromes are congenitally linked to the majority of congenital microstomia cases. Surgical removal of orofacial neoplasms, maxillofacial trauma, burns, cleft lip, radiation, scleroderma, or oral sub mucous fibrosis are other potential causes.

Patients with microstomia may experience a variety of clinical concerns, such as severe facial scarring, narrower lips, decreased lip mobility, and altered anatomy of the oral tissues, including thickening of the labial and buccal tissues and contraction of the tissues around the mouth. The quality of life associated to oral health is impacted by certain characteristics, such as difficulty speaking, impaired chewing.

Oral sub mucous fibrosis is a slowly progressive chronic disease confined to the oral cavity. Its exact etiology is unknown, but the main contributing factors are betel nut and tobacco chewing. Sub mucous fibrosis is characterized by mucosal rigidity due to fibro elastic transformation of juxta epithelial layers leading to inability to open mouth and

dehydration of tissues due to decreased salivary secretion. Prosthodontic rehabilitation of a patient with microstomia is challenging and present difficulties in all clinical steps.

#### CASE DESCRIPTION

A 46 year old female patient came to the Department of Prosthodontics with the chief complaint of missing teeth and wanted replacement to improve her aesthetics and phonetics (Fig 1).

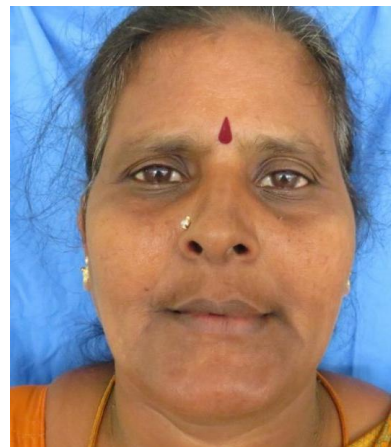

Figure 1: Pretreatment extraoral view

<sup>a</sup> Post Graduate Student, Department of Prosthodontics, Sri Ramakrishna Dental College and Hospital, Coimbatore

<sup>b</sup> Professor Department of Prosthodontics, Sri Ramakrishna Dental College and Hospital, Coimbatore.

<sup>c</sup> Professor & HOD, Department of Prosthodontics, Sri Ramakrishna Dental College and Hospital, Coimbatore.

<sup>d</sup> Senior lecturer, Department of Prosthodontics, Sri Ramakrishna Dental College and Hospital, Coimbatore.

A thorough history revealed habit of tobacco chewing, since last 15 years. As a result she was diagnosed with oral sub mucous fibrosis for which she underwent treatment with intralesional injections in the form of dexamethasone and chymotrypsin that provided only marginal improvement. On intraoral examination, the patient was completely edentulous with restricted mouth opening of 38 mm. The period of edentulousness was 1 year. Intra oral examination revealed lack of elasticity and compressibility of the mucosa and fibrosis of buccal mucosa indicative of Oral sub mucous fibrosis.

#### Treatment planning :

While making the primary impressions, the degree of difficulty was assessed and a sectional denture was planned for the maxillary arch and a conventional denture for the mandibular arch.

#### Clinical procedure :

##### 1. Primary impressions:

The primary impression of maxillary and mandibular arches were made using impression compound (Pinnacle Functional impression compound, DPI India) using stock trays.

##### 2. Final impressions:

The special tray for the maxillary arch was fabricated by using conventional wax spacer design and light cure special tray material (Elite LC Tray, Zhermack, Germany). Multiple tissue stops were given in the spacer to facilitate proper orientation of the tray during the procedure. It was fabricated in two sections and joined using die pins (Fig 2). Sectional border molding was done using putty impression material (Elite HD+, Zhermack, Germany) and secondary impression was made with low-viscosity polyvinyl siloxane impression material (Elite HD+,Zhermack,Germany).Later the two sections were approximated by using die pins to obtain a single impression, for pouring the master cast.

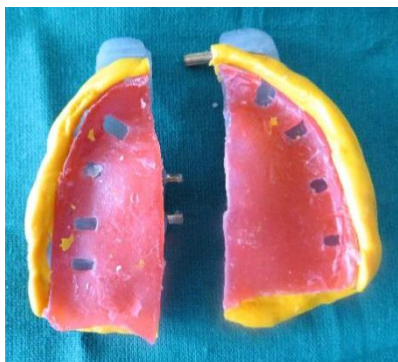

Figure 2: Border moulding done in sections

The mandibular special tray was fabricated as a single piece using self-cure acrylic resin (DPI, India)

and border molding was done with putty impression material (Elite HD+,Zhermack,Germany) followed by secondary impression with low-viscosity polyvinyl siloxane (Elite HD+,Zhermack,Germany) impression material (Fig 3). The master cast was poured using type 3 dental stone.

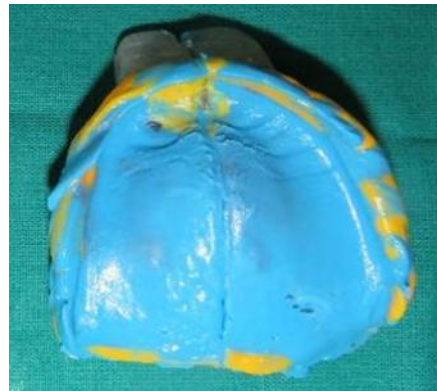


Figure 3: Secondary impressions

##### 3. Fabrication of permanent denture bases :

The maxillary master cast was duplicated using putty impression material, to obtain the master cast as and when needed, during the fabrication of the sectional permanent denture bases. First, one half of the master cast was waxed up after incorporating 3mm diameter commercially available samarium magnets (Magneticks, India), one each in the region of anterior alveolar ridge and mid palatal raphe region. These magnets were stabilised in position using cyanoacrylate. This was acrylised using heat cure acrylic resin (DPI, India), finished and polished. (Fig 4)

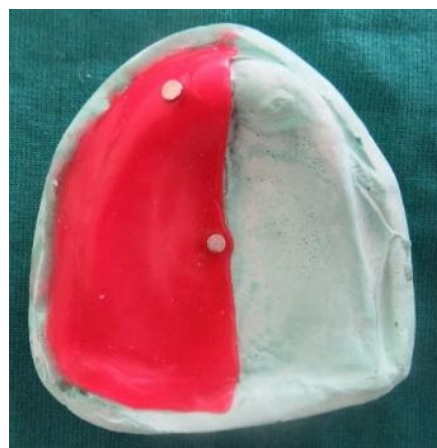

Figure 4: Wax up for duplication

This section was fused to the master cast and was duplicated, to facilitate fabrication of the counter part or the other section of the denture base with the samarium magnets. These were stabilised with cyanoacrylate as previously stated.

4. Jaw relation using the permanent denture bases with occlusal rims fabricated:

The occlusal rims were fabricated over the permanent sectional denture bases and jaw relation recording was done and mounted on mean value articulator.

5. Teeth setting and wax try in:

Teeth setting and wax try in was carried out in a conventional manner using the sectional denture bases with the occlusal rims on the maxillary cast and conventional denture base with occlusal rim on the mandibular cast. The wax try-in was satisfactory and aesthetically pleasing to the patient. (Fig 5)

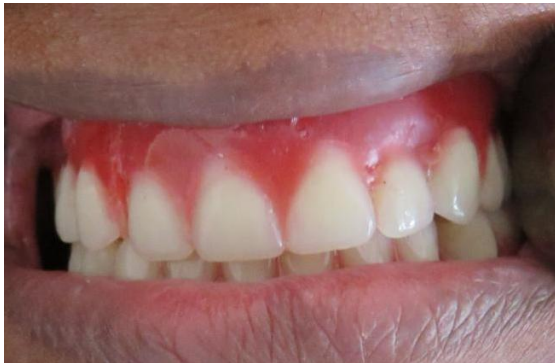

Figure 5: Wax try in

6. Acrylisation and insertion:

An additional samarium magnet of size 5mm in diameter was placed towards the posterior most part of the mid palatal raphe region to enhance the approximation of the sectional denture bases. (Fig 6)

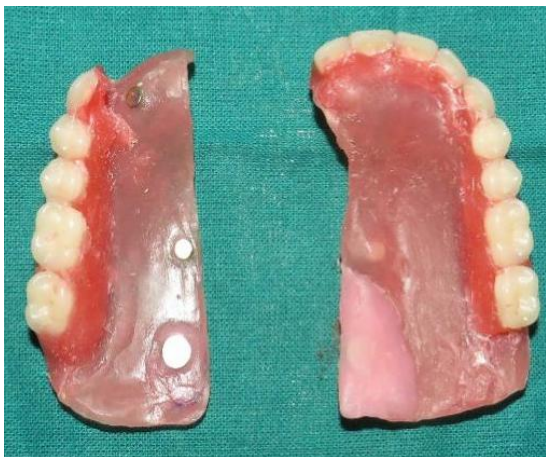

Figure 6: Waxed up dentures with magnet attached posteriorly

Each half of the maxillary sectional denture (Fig 7, Fig 8) was acrylised using minimal amount of heat cure acrylic resin, only to facilitate the acrylisation of teeth bearing areas.

The dentures were inserted and evaluation of phonetics and aesthetics was done, and was found to be satisfactory. (Fig 9, Fig 10)

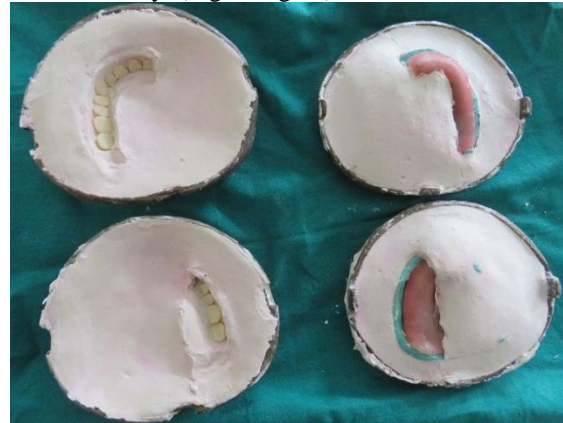

Figure 7: After dewaxing

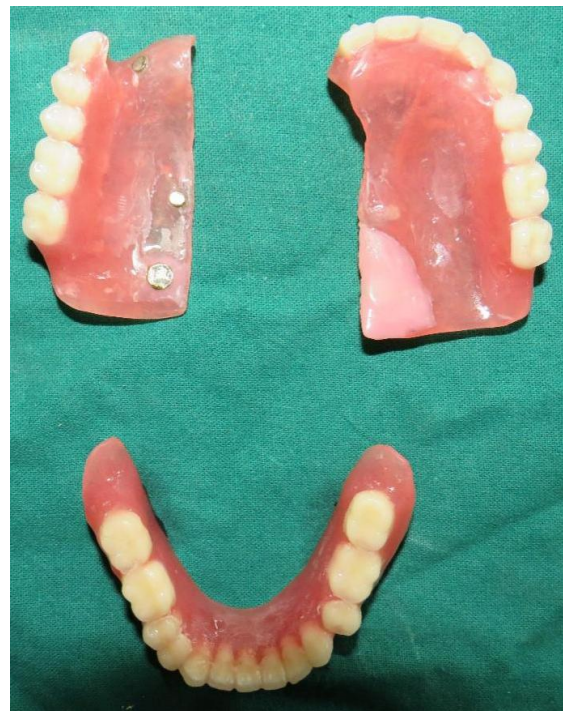

Figure 8: Acrylised and finished dentures

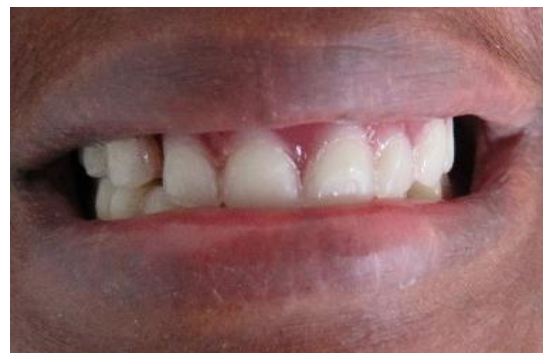

Figure 9: Satisfactory aesthetics and occlusion after denture insertion

## DISCUSSION

A planned and sequential approach is essential in treating microstomia cases. As the outcome is dependent on the clinical complexity of the case, along with the use of recommended materials and armamentarium, therefore, diagnosis and treatment planning are an essential component in the management. A sectional complete denture prosthesis was provided based on the patient's treatment motivation and available treatment duration.

The present technique involved the fabrication of a sectional maxillary complete denture and conventional mandibular complete denture, as the patient was able to insert the mandibular denture by rotating it.

The secondary impression was made in two different sections using putty and low viscosity polyvinyl siloxane impression material. The jaw relation was done using permanent denture bases

fabricated in sections. Teeth arrangement and wax try in was done and the dentures were inserted after acrylisation, trimming, finishing and polishing.

Aesthetics was satisfactory and improvement in phonetics was observed. The patient was trained to insert and remove the maxillary denture in sections. A similar technique in which instead of samarium magnets, press button was utilised in the mid raphe region to hold the sections together.<sup>4</sup> It was found to be convenient to use due to ease of insertion and removal. It was a practical and economical option for the fabrication of sectional denture.

Another technique was recommended in which maxillary and mandibular sectional dentures were fabricated by incorporation of Co-Cr hinge at the centre and ball abutments at the periphery of the posterior abutment.<sup>7</sup> This allowed for two-part insertion and enhanced stability due to the engagement of ball abutments and central hinge.

It is pertinent to mention that the success of prosthodontic treatment provided is multifactorial and improvement in mouth opening, soft and hard tissue health, and discontinuation of habits, good oral hygiene, and regular maintenance of prosthesis are critical for good treatment prognosis.

A novel technique was given which proposed a digital approach to treatment of an edentulous patient with microstomia.<sup>5</sup> Preliminary impressions were made using a high resolution intraoral scanner, even though difficulties were encountered while recording displaceable soft tissues. Further laboratory steps were performed in a conventional manner and dentures were inserted.

CAD/CAM technology in prosthodontics offers patient comfort and reduction in the number of clinical appointments. However, use of digital technologies in edentulous arches does not simplify the procedures for complete denture fabrication.

When CAD/CAM technology finally allows accurate recording of mobile soft tissues for final

impressions of edentulous arches, we will be a step closer to a fully digital complete denture fabrication workflow.

## CONCLUSION

The use of sectional removable dentures in the rehabilitation of edentulous patients with microstomia is effective; however, Treatment prognosis is dependent on patient motivation and adaptation, case complexity, prosthodontic technique, technical skill, and maintenance

## CONFLICT OF INTEREST

There is no conflict of interest

## REFERENCES

1. McCord JF, Tyson KW, Blair IS .A sectional complete denture for a patient with microstomia. J Prosthet Dent.1989.61:645–647
2. Moghadam BK.Preliminary impression in patients with microstomia. J Prosthet Dent.1992. 67:23–25
3. Suzuki Y, Abe M, Hosoi T, Kurtz KS.Sectional collapsed denture for a partially edentulous patient with microstomia: A clinical report. J Prosthet Dent.2000. 84:256–259
4. Cura C, Cotert HS, User A.Fabrication of a sectional tray and sectional complete denture for a patient with microstomia and trismus: A clinical report. J Prosthet Dent.2003.89(6):540–543
5. Geckili O, Cilingir A, Bilgin T: Impression procedures and construction of a sectional denture for a patient with microstomia: a clinical report. J Prosthet Dent. 2006.96(6):387-390
6. Gauri M, Ramandeep D. Prosthodontic Management of a Completely Edentulous Patient with Microstomia: A Case Report. J Indian Prosthodont Soc .2013.13(3):338–342
7. Sinavarat P and Anunmana C, Sectional collapsible complete removable dental prosthesis for a patient with microstomia. J Prosthet Dent.2015.114(5): 627-632
8. Saygili S,Geckili O, Sulun T. Prosthetic Rehabilitation of an Edentulous Patient with Microstomia Using Both Digital and Conventional Techniques: A Clinical Report. Journal of Prosthodontics.2019.28(5): 488-492
9. Soleimani F, Yaghoobi N, Niakan S. Complete Denture with Sectional-Tray Approach in a Microstomia Patient: A Case Report and Literature Review. International Journal of Scientific Research in Medical and Dental Sciences.2021.3(2)94-100
10. Abbasi S M et al. Management of Edentulous Microstomia Patient: A Case Report and Classification System.Case reports in dentistry.2022

**Corresponding Author:** Dr. Amrutha S Sankarana, Post Graduate Student, Department of Prosthodontics, Sri Ramakrishna Dental College and Hospital, Coimbatore.  
E-mail: [20mds02@srdch.ac.in](mailto:20mds02@srdch.ac.in) , Ph.No.: +91 8714816322

*Copyright by the Editorial board for The Journal of Clinical Prosthodontics and Implantology*